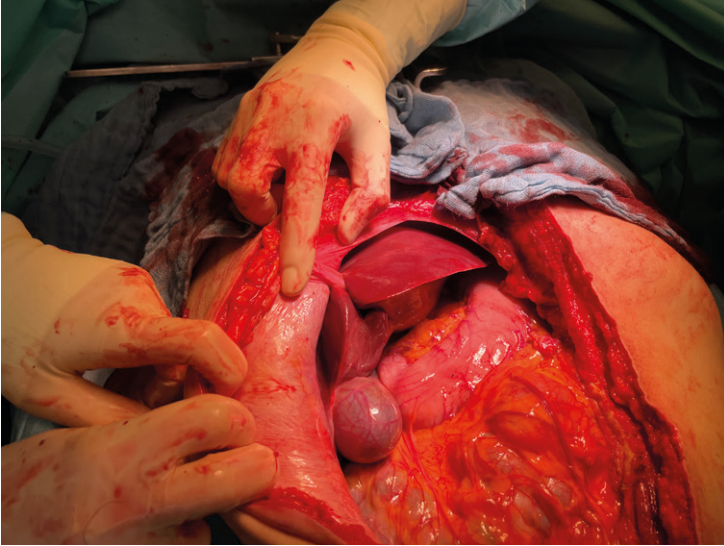
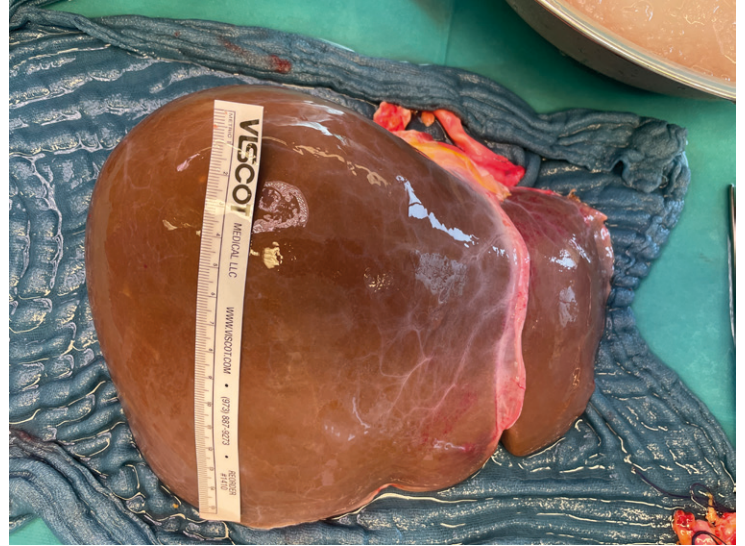

Leber

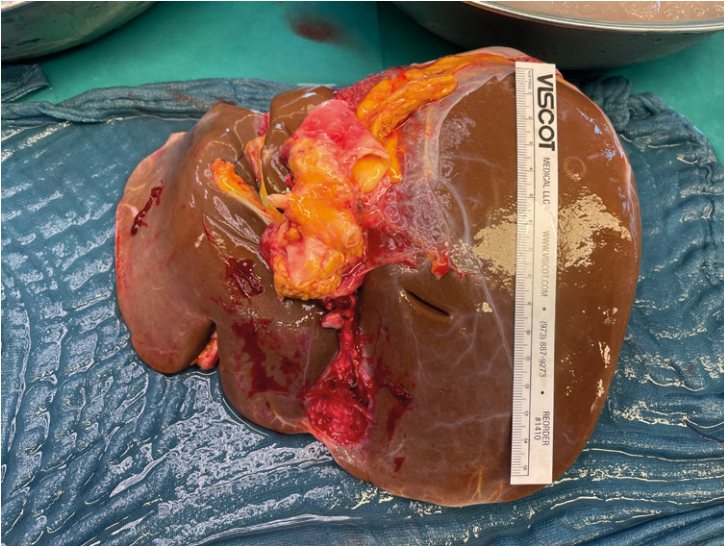
L1 Situs vor Perfusion



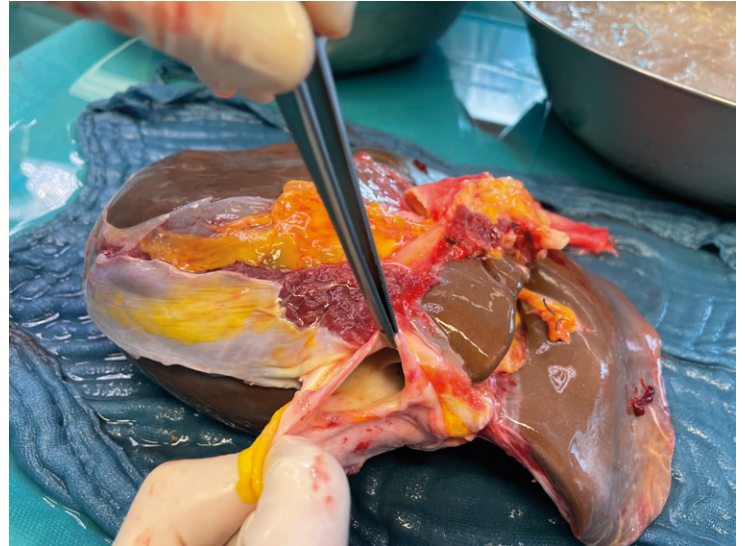
L2 Ventrocranial



L3 Dorsocaudal inkl. Strukturen Ligamentum hepatoduodenale

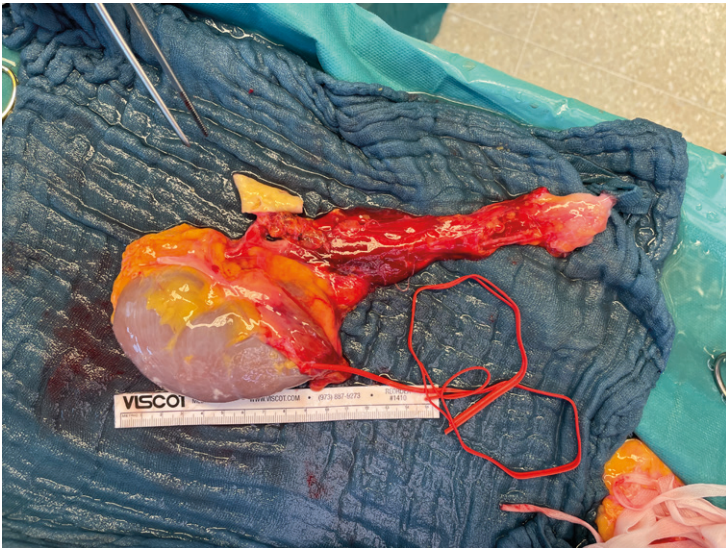


L4 Suprahepatische V. cava inf.

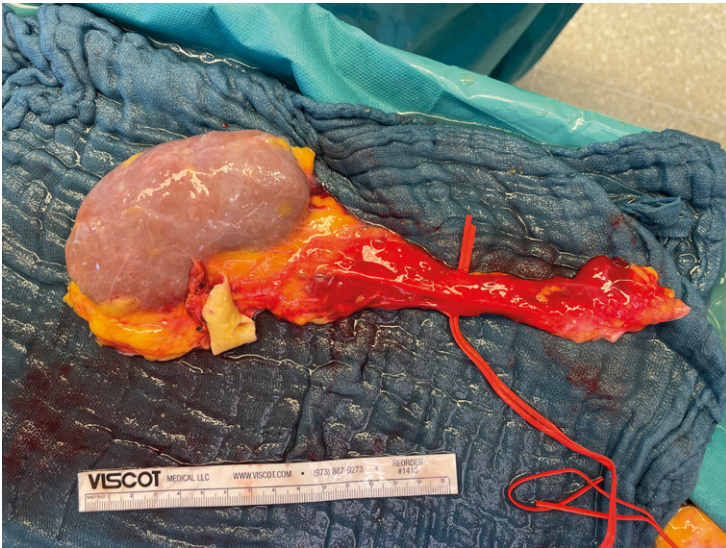


Niere

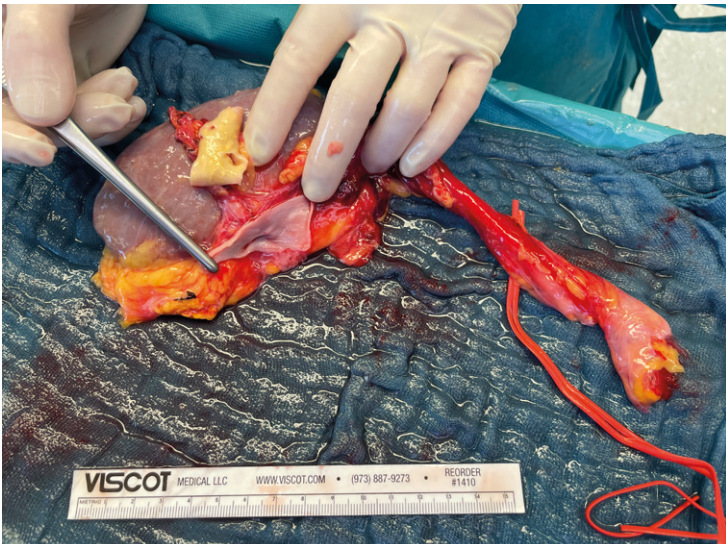
N1 Ventral inkl. Ureter und Golden Triangle



N2 Dorsal

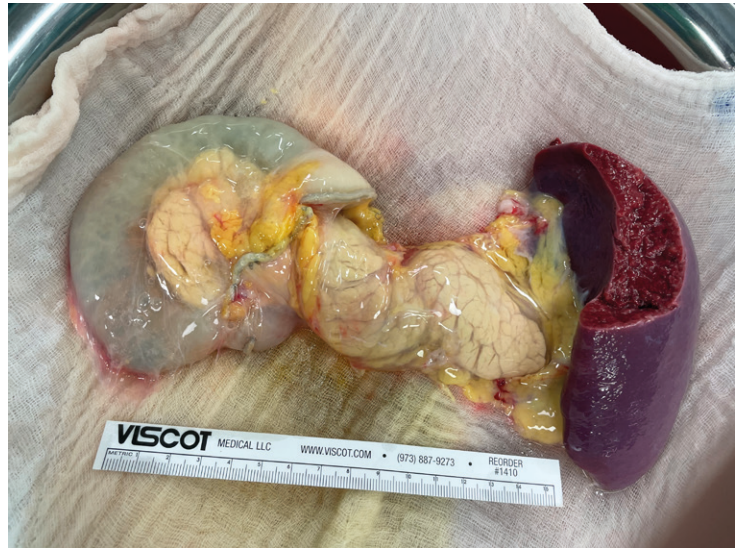

N3 Aorten- und Venenpatch

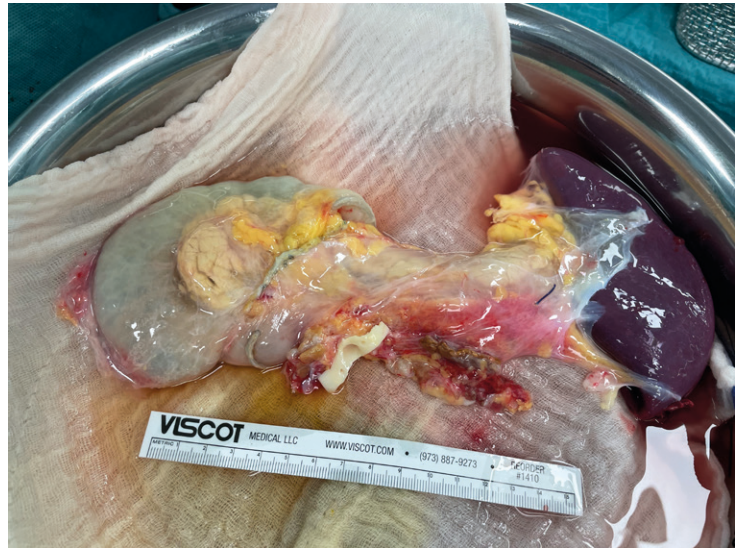

Pankreas

P1 Ventral inkl. Duodenum, Milz, mesenterialer Absetzungsrand



P2 Dorsal inkl. Duodenum, Milz, mesenterialer Absetzungsrand



P3 Pfortader

